

Bisphosphonate-related osteonecrosis of the jaw (BRONJ): 5 year experience in the treatment of 131 cases with ozone therapy

A. AGRILLO, F. FILIACI, V. RAMIERI, E. RICCARDI, D. QUARATO, C. RINNA,
P. GENNARO, F. CASCINO, V. MITRO, C. UNGARI

Department of Maxillo-Facial Surgery, Umberto I Polyclinic, Sapienza University of Rome, Rome, Italy

Abstract. – BACKGROUND: Bisphosphonate-Related Osteonecrosis of the Jaw (BRONJ) are the result of the assumption of such drugs. The most widely used molecules are pamidronate and zoledronic acid, which are pyrophosphate analogues and are usually given to patient with bone remodelling diseases. International literature reports showed an association between this therapy and avascular necrosis, thus leading to review the guidelines for their administer.

AIM: The authors present their protocol based upon medical treatment, antibiotic and antimycotic, together with minimally invasive surgery and ozone therapy developed after a 5 year experience to assess the viability of this treatment.

MATERIALS AND METHODS: In the last years researchers studied treatment protocols, both medical and surgical, for the management of BRONJ. Among these Ozone therapy is being adopted by several centers. From February 2004 and December 2010 a total number of 131 patients affected by BRONJ have been observed. Collected data include patients' age at the time of disorders, gender, presenting signs and symptoms, primary diagnosis, type and characteristics of the treatment performed, radiological findings and post-treatment results.

CONCLUSIONS: At the present time there are no major guidelines in international literature for the treatment of BRONJ, the Authors then propose a therapeutic protocol based upon minimally invasive surgery, antibiotic and anti mycotic therapy with the adoption of ozone as regenerating factor for tissues. In 90% of the cases the results confirmed the procedure with successful outcomes.

Key Words:

BRONJ treatment, Ozonotherapy, Biphosphonates, Pamidronate, Zoledronic acid.

Introduction

Bisphosphonate-Related Osteonecrosis of the Jaw (BRONJ) are the result of the assumption of

such drugs¹⁻³. These medicines are widely adopted for the treatment of pathologies such as, multiple myeloma, bone metastasis of mammarian and prostatic cancer or malignant hypercalcaemia and osteoporosis.

The most widely used molecules are pamidronate and zoledronic acid, which are pyrophosphate analogues and are usually given to patient with bone remodelling diseases.

These drugs act by reducing osteoclasts bone resorption throughout different pathways such as inhibition of proton pump, necessary for the dissolution of hydrossiapatite, reduction of formation/activation of the osteoclasts and induction of their apoptosis^{3,4}.

Besides the reduction of bone metastasis onset, benefits are: prevention of pathologic fractures, pain reduction, improving quality of life.

Nevertheless some international literature reports showed an association between this therapy and avascular necrosis, thus leading to review the guidelines for their administer.

BRONJ lesions may remain silent till the occurrence of outcoming events such as oral traumas (prosthesis, surgical extraction or oral surgery) which might exposes the bone to bacterial colonization.

The clinical manifestation may vary from simple swellings of soft tissues, abscesses, bone exposure to more complex cases presenting with fistulas, phlegmon, chewing or vocal impairment and diffuse pain⁵.

In the last years researchers studied treatment protocols, both medical and surgical, for the management of BRONJ⁶.

The Authors present their protocol based upon medical treatment, antibiotic and antimycotic, together with minimally invasive surgery and ozone therapy developed after a 5 year experience^{7,8}.

The rationale for the adoption of ozone therapy is to enhance any other possible treatment

such as minimally-invasive surgical procedures. We can acknowledge non surgical dental extraction in these procedures to avoid traumatic exposure of bony lesions.

There is no known contraindication for topic ozone therapy with OZONYTRON® GmbH.

Materials and Methods

The Authors performed a retrospective study in all patients observed from February 2004 to December 2010 at the Department of Maxillo-facial Surgery of “Sapienza” University of Rome. A total number of 131 patients affected by BRONJ was visited. Collected data include patients' age at the time of disorders, gender, presenting signs and symptoms, primary diagnosis, type and characteristics of the treatment performed, radiological findings and post-treatment results.

Out of this number 82 were females and 49 males, the mean age was 60 years with a lowest value of 38 and higher of 82. All patients came to our observation with a history of biphosphonates treatment for different pathologies. Out of the whole sample 56 were affected by multiple myeloma (43.3%), 41 by mammarian cancer (31.49%), 8 by prostatic cancer (5.5%), 11 by lung cancer (7.87%), 8 by kidney cancer (6.3%), and 7 by osteoporosis and other diseases such as lymphomas, thyroid cancer and connectivitis (5.5%). Patients were divided by age, number of lesions of upper and lower maxilla. Lesions of upper maxilla occurred in 43 patients (33%), 73 had only mandible lesions (55.2%) and 15 present bi-maxillary necrotic involvement (11.8%).

Out of the 131 we observed 70 (52%) came for pain symptoms after dental extraction with exposure of necrotic bone in the same area. Only 36 (27.5%) patients complained for pain and spontaneous exposure of alveolar bone despite of their negative records for odontoiatric procedures.

Diagnosis was based upon anamnestic and clinical evaluation together with ortopantomography x-rays scan and dental scan computed tomography.

All the patients presented bony exposures and for this reason indication was given for Ozone therapy in association non-invasive surgical interventions (sequestrectomy).

Unfortunately 37 patients withdrawn our protocol. The main reason was relied to the distance

from our Service as we observed patients from all over the nation.

Ninety-four (94) patients of the sample of 131 then underwent our protocol. None of the patients under our protocol underwent was allowed for any dental procedure for the whole period of the treatment.

Our protocol is based upon the following schedule: removal of bone sequestrum and Ozone therapy with 3 minutes sessions twice a week. Moreover every patient was administered with β -lactamics antibiotics, anti-mycotic, ascorbic acid together with chlorhexidine 0.2% mouth rinses till the complete resolution of clinical findings.

The surgical treatment was based upon conservative curettage of the bony lesion (without the use of any drill or traumatic procedure) or sequestrectomy.

In almost every case we didn't raise any local flap of mucosa or performed sutures; instead we simply stuffed the residual cavity with greasy gauzes without any subperiosteal dissection.

Patients were taught to do mouth rinses with sterile sodium hypochlorite 0.05% along the treatment.

Moreover 94 patients out of the 131 treated with our protocol underwent surgical procedures in local anaesthesia and we didn't observe any complications.

Only nine patients underwent general anaesthesia surgical wide bone excision considering the extension of the sequestrum. In 3 cases we had to reconstruct the mandible with titanium plates due to the necessity for a bicortical complete bone asportation.

Success criteria were set as follows: complete mucosal healing and closure of the primary lesion without symptoms such as pain or local swelling or inflammation.

Results

94 patients participated in the study: these are 59 women and 35 men. The mean age was 57 years old with a lowest value of 38 and higher of 82. Lesions of upper maxilla occurred in 31 patients (33%), 52 had only mandible lesions (55%) and 11 present bi-maxillary necrotic involvement (12%). The 94 patients we enrolled in our protocol, as reported before, underwent a mean value of 1.75 surgical treatment and 4 cycles of ozone therapy with an observation period of 6.5 months (mean value).

Table I. T test to evaluate pre and post operative pain

N	Mean	Std Dev	Std Err	Min	Max
94	0.2766	0.4497	0.0464	0	1
Mean	95% CI Mean		Std Dev	95% CI Std Dev	
0.2766	0.1845	0.3687	0.4497	0.3933	0.5251
DF	T value	Pr >[T]			
93	5.96	<.0001			

Pre and post operative pain were evaluated and a statistical analysis with a T test was performed. The 94 patients sample and we referred the following values: pre op pain 27.6%, post op pain 0%. The analysis highlighted a $p < 0.001$ compatible with the hypothesis that ozone therapy has a predictable effect on pain (Table I).

In addition we estimated treatment outcomes according to three possible eveniences: complete resolution with diminishing of symptoms that occurred in 57 patients (60%); in 28 cases (30%) a marked reduction of the lesions, with improvement of symptoms, was observed whilst in 9 patients (10%) we reached only a partial healing from symptoms without any result with the lesion.

The Wilcoxon signed Rank Test was performed showing a $p < 0,001$ consistent with the effect we clinically observed on lesion healing due to ozone therapy (Table II).

None of the patients who underwent dental extraction had complications such as primary lesion expansion or new necrotizing spots.

Discussion

The first descriptions of such osteonecrosis are dated 2003¹. In 2004 more relevant reports are described by Marx⁹, the work described 36 cases being 18 affected by multiple myeloma, 17 by mammarian neoplasms and 1 patient by osteoporosis. This group underwent medical treatment

Table II. Wilcoxon signed rank test to evaluate the three possible therapy outcomes.

Tests for location $\mu_0 = 0$				
Test	Statistic			p-value
T of student	t	36.44359	Pr > [t]	< 0.0001
Signed	M	47	Pr ≥ [M]	< 0.0001
Signed rank	S	2232.5	Pr ≥ [S]	< 0.0001

with pamidronate and zoledronic acid and they presented areas of exposed and necrotic maxillary bone. In 28 cases it was consequence of dental extraction or spontaneous events in 8 patients.

In 2004 Ruggiero et al³ presented a wider case series of 63 cases of BRONJ. Patients were mainly oncologic (multiple myeloma, mammarian and prostatic cancer), with at least 1 year of treatment with biphosphonates, with areas of exposed bone, with bacterial superinfection and massive pain after dental extraction or minor oral surgery procedure.

In this paper Authors mainly highlighted the extreme difficulty of managing this clinical condition in particular the failure of surgery being responsible most of the times for worsening of the areas of necrosis.

Greenberg¹⁰ in September 2004 warned the world of oral surgery about the outcoming problem of BRONJ. He suggested caution in those patients in therapy with biphosphonates. He suggested a very careful clinical examination before starting this protocol in order to schedule in time eventual oral surgery procedures¹⁰.

Ischemic necrosis of the jaws is a non-specific bone lesion, characterised by a slow progression and impossibility for spontaneous healing. It can't be considered an autonomous disease but it is the consequence of several local and systemic factors capable of modifying the bony haematic flow and surroundings tissues thus leading to exposition of external worsening features¹¹.

Indeed, every single pathologic or traumatic issue might be responsible for osteonecrosis as a consequence of hypoxia, hypocellularity and hypovascularization^{1,5}.

The process might result from dental extraction or any other traumatic issue that can cause alveolar bone loss. It can be observed in patients who underwent radiotherapy of the head and neck district in 5-15% of cases¹², the so-called osteo-radio-necrosis. Usually in 50% of cases occurs in the mandible after dental extraction.

Moreover many other factors are described such as inflammation or infections, osteomyelitis, steroid local injections, local anaesthetics, bone tumour, mycotic or viral infections and necrotizing sialometaplasia. Dealing with hyatrogenic causes endodontic treatment accidental diffusion has been described⁵.

Staging

At the present time many different classification have been proposed with the aim of standardizing BRONJ and their treatment. Ruggiero et al³ are between of the first Authors who proposed a clinical classification (Table III).

However, clinical manifestation of BRONJ are variable with different progression and associated symptoms. In 2006 the AAOMF constituted a Task Force¹⁴ made up of experts and epidemiologists who studied the existent literature with the final goal of drawing guidelines. The same team in February 2009 introduced some upgrades because of the increasing incidence of the pathology. Patients were then divided into 2 categories:

1. Patients at risk: No apparent necrotic bone in asymptomatic patients who have been treated with IV or oral biphosphonates.
2. Patients with BRONJ

Moreover, a new therapeutic strategy was introduced:

- Patients at risk didn't need any treatment.
- *Patient in Stage 1*: These patients benefit from the use of oral antimicrobial rinses, such as chlorhexidine 0.12%. No surgical treatment is indicated.
- *Patients in Stage 2*: Use of oral antimicrobial rinses in combination with antibiotic therapy. (penicillines are the most specific for bacterial flora). Microbial cultures should also be analyzed for the presence of actinomyces species of bacteria.

Table III. Clinical classification of BRONJ.

<p>Stage 1: Exposed necrotic bone without symptoms</p> <p>Stage 2: Exposed necrotic bone with pain and infection</p> <p>Stage 3: Exposed necrotic bone with pain and infection and pathologic fractures, extra oral fistulas, or signs of osteolysis extending to the inferior cortical border.</p>
--

- *Patients in Stage 3*: These patients benefit from debridement including resection, in combination with antibiotic therapy, which may offer long-term palliation with resolution of acute infection and pain.

Whenever sequestrum occurs, without regard for the strategy, it has to be removed. Dental extraction for element in proximity of bone exposure can be performed if it wouldn't cause necrotic process.

Other international studies aimed at identifying the best approaches for the management of this disease, for example in 2007 the American Society for Bone and Mineral Research¹⁵ introduced other indications for the treatment and classifications on the basis of AAOMS.

This task force suggested the best x-rays examination tests for diagnosis and monitoring, (ortopantomography, CT scan, bone scintigraphy with Tc^{99m}). However, other exams are under observation for the interceptive identification of the lesions. Clinical recommendations for general practitioners and patients have been proposed too on the basis of the stage of the pathology. Moreover, an animal model to evaluate the efficacy of drugs and their effect on bone has been investigated too.

Dealing with these aspects, considering their clinical findings, the Authors present a further classification system for BRONJ. Besides localization and dimension of the lesions it is possible to distinguish two different patterns of appearance and behaviour that we define: wet and dry.

The *dry* pattern appears like bone exposition without exudate, often not painful with a poor inflammatory reaction of the surrounding tissues. This type it's frequently observed in patients with progression of the disease and who are under chemotherapy or biphosphonates treatment; there are no signs of immunity response against the lesion.

The *wet* pattern appears with lesions rich of inflammatory infiltration, purulent exudate, pain, presence of fistulas. More often it occurs in patient with good general conditions and with a stable stage of the underlying disease. Usually a bone sequestrum is present. In those patients the prognosis is favourable.

Recently the Board of the Italian Societies for Maxillofacial Surgery (SICMF) and Oral Pathology and Medicine (SIPMO) appointed a Panel of experts for the study of bisphosphonate-related osteonecrosis of the jaws. According to this group: "bisphosphonate related os-

teonecrosis of the jaw (BRONJ) is an adverse drug reaction described as the progressive destruction and death of bone that affects the mandible or maxilla of patients exposed to the treatment with nitrogen-containing bisphosphonates, in the absence of a previous radiation-treatment^{16,17}. Moreover, the same group proposed a new classification for BRONJ:

Clinical and Radiological Staging System of Bisphosphonate Related Osteonecrosis of the Jaws (BRONJ)

Stage 1 Focal BRONJ

Clinical signs and symptoms: bone exposure; sudden dental mobility; nonhealing postextraction socket; mucosal fistula; swelling; abscess formation; trismus; gross mandibular deformity and/or hypoesthesia/paraesthesia of 18 the lips

CT findings: increased bone density limited to the alveolar bone region (trabecular thickening and/or focal osteosclerosis), with or without the following signs: 19 markedly thickened and sclerotic lamina dura; persisting alveolar socket; and/orcortical disruption

- 1a. Asymptomatic
- 1b. Symptomatic (pain and purulent discharge)

Stage 2 Diffuse BRONJ

Clinical signs and symptoms: same as Stage 1
CT findings: increased bone density extended to the basal bone (diffuse osteosclerosis), with or without the following signs: prominence of the inferior alveolar nerve canal; periosteal reaction; sinusitis; sequestra formation; and/or oro-antral fistula

- 2a. Asymptomatic
- 2b. Symptomatic (pain and purulent discharge)

Stage 3 Complicated BRONJ

Same as Stage 2, with one or more of the following: clinical signs and symptoms: extra-oral fistula; displaced mandibular stumps; nasal leakage of fluids CT findings: osteosclerosis of adjacent bones (zygoma, hard palate); pathologic mandibular fracture.

The Ozone Therapy

After careful review of the international literature it is clear that the surgical excision of the necrotic area in BRONJ represents the most used approach even if it is not sufficient to arrest the progression of the pathologic process itself. The same can be assessed for antibiotic therapy. Afterwards we decided to apply a mini invasive sur-

gical approach together with medical therapy and Ozonotherapy. The combination of these strategies consents to accomplish very surprising results in the treatment of BRONJ considering that at the present time there is no accepted international treatment protocol^{18,19}.

The adoption of ozonotherapy revealed to enhance and adjuvate the procedures we performed. The therapeutic range is nowadays documented for several pathologies in association with other strategies. Its main features are: antimicrobial power, against aerobic and anaerobic bacteria (in particular staphylococcus aureus) mycetes and viruses^{20,21}; circulatory system stimulation increasing hemoglobine ratio and red blood cells thus enhancing tissue oxygenation; it modulates the response of immunitary cells, acting like a cytokine, improving phagocytosis and diapedesis of phagocytes; moreover, it stimulates angiogenesis and fibroblasts formation²² together with pain reduction.

Ozone induces the formation of bone sequestrum, enhances vascularization of the underlying bone and stimulates the formation of granulating tissues. Consequently the excision of such lesion exposes a regenerating tissue that is not necessary to treat surgically (Figure 1).

Ozone therapy can be performed with different devices according to clinical needs: It can be dealt in the following ways: autohemotherapy consisting in the exposition of blood to a mix of oxygen and ozone as used in chronic atherosclerosis of lower limb, in ischemic disease, in age-related retinal maculopathy²³; otherwise intramuscular injections for the treatment of discal herniation are very commonly adopted or chronic arthritis (minor autohemotherapy)²⁴; local treatment are described too for the management of dental caries, insufflation, ozonized water or oil^{25,26}.

In a study of 1999 Steinhart et al²⁷ underlined how resistant osteomyelitis of head and neck of rat bony models, may benefit from combined antibiotic therapy, localized ozone application and surgery. This is due not only to fibroblasts activation and neoangiogenesis but also to the bactericide effect against *Staphylococcus aureus*²⁷.

The treatment could be planned with a previous surgical resection of the affected bone area followed by local application of oxygen-ozone together with antibiotics.

The Authors introduced the adoption of ozonotherapy in patients affected by BRONJ achieving the 90% of symptoms remission^{7,8}; obviously this is not a substitute of existing proce-

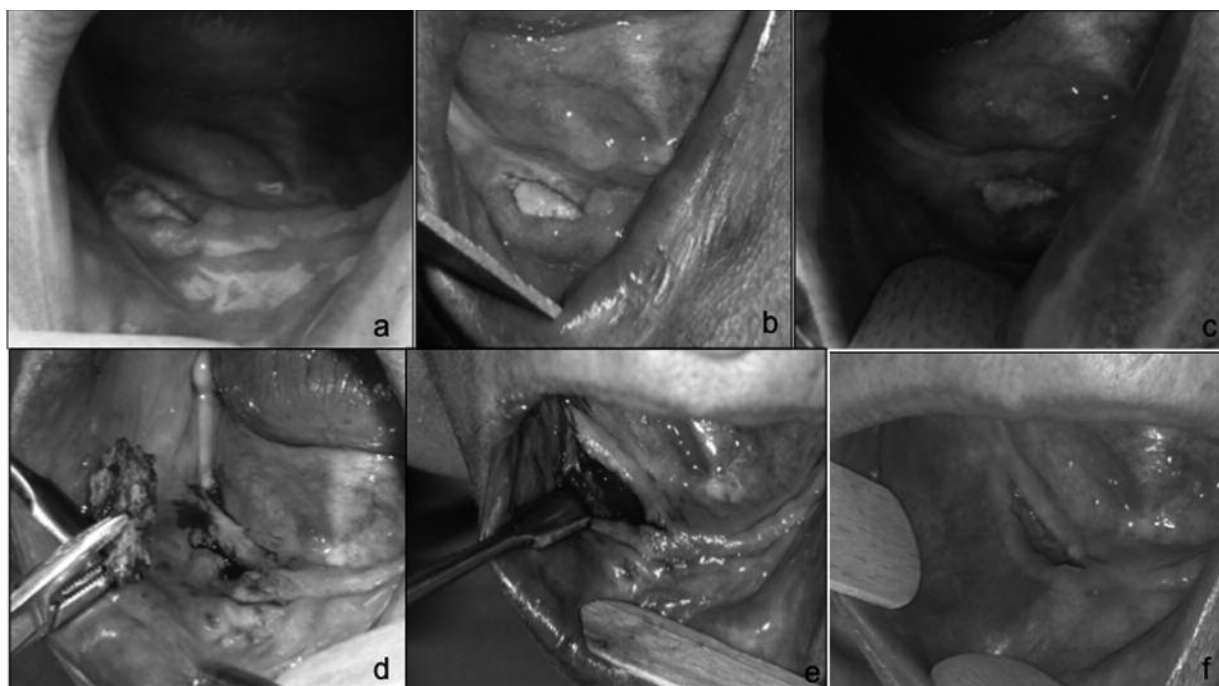


Figure 1. *A*, Before treatment with ozone. *B*, After the first cycle of ozone-therapy. *C*, After the second cycle of ozone-therapy. *D*, Sequestrectomy. *E*, After 1 week from sequestrectomy. *F*, After 2 months from sequestrectomy.

dures but it might be considered as a fundamental pre and post-operative step to improve patient's life quality.

Surgical treatment should aim to a wide and complete excision of the lesion. Unfortunately this is not always achievable. We can then consider the occurrence of bone sequestrum as a favourable condition in the prognostic index, because very often after the removal of bone sequestrum a vital tissue with well vascularized mucosa can be observed.

Conclusions

At the present time there are no major guidelines in international literature for the treatment of BRONJ, the Authors then propose a therapeutic protocol based upon minimally invasive surgery, antibiotic and anti mycotic therapy with the adoption of ozone as regenerating factor for tissues. In 90% of the cases the results confirm the procedure. We recommend the appropriate oncologic and hematologic counselling for the eventual cessation of biphosphonates and a further dentistry evaluation for eventual extractions or oral surgery procedures in cooperation with the maxillo-facial surgeon

in order to avoid more severe lesions. In a near future the adoption of different devices such as ozonized water or autohemotherapy could represent a viable procedure for the treatment of this very difficult pathology.

References

- 1) WANG J, GOODGER NM, POGREL MA. Osteonecrosis of the jaws associated with cancer chemotherapy. *J Oral Maxillofac Surg* 2003; 61: 1104-1107.
- 2) OLSON KB, HELLIE CM, PIENTA KJ. Osteonecrosis of the jaw in patient with hormone refractory prostate cancer treated with Zolendronic acid. *Urology* 2005; 66: 658-661.
- 3) RUGGIERO SL, MEHROTRA B, ROSENBERG TJ. Osteonecrosis of the jaws associated with the use of biphosphonates: a review of 63 cases. *J Oral Maxillofacial Surg* 2004; 62: 527-534.
- 4) FOURNIER P, BOISSIER S, FILLEUR S, GUGLIELMI J, CABON F, COLOMBEL M, CLÉZARDIN P. Biphosphonates inhibit angiogenesis in vitro and testosterone-stimulated vascular regrowth in the ventral prostate in castrated rats. *Cancer Res* 2002; 15: 6538-6544.
- 5) AMERICAN ASSOCIATION OF ORAL AND MAXILLOFACIAL SURGEONS. Position Paper on Bisphosphonate-Related Osteonecrosis of the Jaws. *J Oral Maxillofac Surg* 2007; 65: 369-376.

- 6) BAMIAS A, KASTRITIS E, BAMIA C. Osteonecrosis of the jaw in cancer after treatment with bisphosphonates: incidence and risk factors. *J Clin Onc* 2005; 23: 8580-8587.
- 7) AGRILLO A, UNGARI C, FILIACI F, PRIORE P, IANNETTI G. Ozone therapy in the treatment of avascular bisphosphonate-related jaw osteonecrosis. *J Craniofac Surg* 2007; 18: 1071-1075.
- 8) AGRILLO A, SASSANO P, RINNA C, PRIORE P, IANNETTI G. Ozone therapy in extractive surgery on patients treated with bisphosphonates. *J Craniofac Surg* 2007; 18: 1068-1070.
- 9) MARX RE. Pamidronate aredia and zoledronate zometa induced avascular necrosis of the jaws: a growing epidemic. *J Oral Maxillofac Surg* 2003; 61: 1115-1117.
- 10) GREENBERG MS. Intravenous bisphosphonates and osteonecrosis. *Oral Surg Oral Med Oral Pathol Oral Radiol Endod* 2004; 98: 259-260.
- 11) LEON A, ASSAEL J. Oral bisphosphonates as a cause of bisphosphonate-related osteonecrosis of the jaws: clinical findings assessment of risks, and preventive strategies. *J Oral Maxillofac Surg* 2009; 67(1 Suppl): 35-43.
- 12) VIALE PH, LIN H. Exposed bone in Oral Cavities. *Clin J Oncol Nurs* 2005; 9: 355-357.
- 13) RUGGIERO SL, FANTASIA J, CARLSON E. Bisphosphonate-related osteonecrosis of the jaws: background and guide lines for diagnosis, staging and management. *Oral Surg Oral Med Oral Path Oral Rad Endodontol* 2006; 102: 433-441.
- 14) UPDATE AMERICAN ASSOCIATION OF ORAL AND MAXILLOFACIAL SURGEONS. Position paper on bisphosphonate-related osteonecrosis of the jaws. *J Oral Maxillofac Surg* 2009; 67(5 Suppl): 2-12.
- 15) KHOSLA S, BURR D, CAULEY J, DEMPSTER DW, EBELING PR, FELSEBERG D, GAGEL RF, GILSANZ V, GUISE T, KOKA S, MCCAULEY LK, MCGOWAN J, MCKEE MD, MOHLA S, PENDRYG DG, RAISZ LG, RUGGIERO SL, SHAFER DM, SHUM L, SILVERMAN SL, VAN POZNAK CH, WATTS N, WOO SB, SHANE E. Bisphosphonate-associated osteonecrosis of the jaw: report of a task force of the American Society for Bone and Mineral Research. *J Bone Miner Res* 2007; 22: 1479-1491.
- 16) BEDOGNI A, FUSCO V, AGRILLO A, CAMPISI G. Learning from experience. Proposal of a refined definition and staging system for bisphosphonate-related osteonecrosis of the jaw (BRONJ). *Oral Dis* 2012; 18: 621-623.
- 17) CAMPISI G, LO RUSSO L, AGRILLO A, VESCOVI P, FUSCO V, BEDOGNI A. BRONJ expert panel recommendation of the Italian Societies for Maxillofacial Surgery (SICMF) and Oral Pathology and Medicine (SIPMO) on Bisphosphonate-Related Osteonecrosis of the Jaws: risk assessment, preventive strategies and dental management. *Italian J Maxillofac Surg* 2011; 22: 103-124.
- 18) FREIBERGER JJ. The utility of hyperbaric oxygen in the treatment of bisphosphonate-related osteonecrosis of the jaws. *J Oral Maxillofac Surg* 2009; 67(5 Suppl): 96-106.
- 19) AGRILLO A, NASTRO SINISCALCHI E, FACCHINI A, FILIACI F, UNGARI C. Osteonecrosis of the jaws in patients assuming bisphosphonates and sunitinib: two case reports. *Eur Rev Med Pharmacol Sci* 2012; 16: 952-957.
- 20) DAYAS A, BOUGHTON BJ, DAS BC. Ozone killing action against bacterial and fungal species; microbiological testing of a domestic ozone generator. *J Clin Pathol* 1983; 36: 1102-1104.
- 21) MULLER P, GUGGENHEIM B, SHMIDLIN P. Efficacy of gasform ozone and photodynamic therapy on a multispecies oral biofilm in vitro. *Eur J Oral Sci* 2007; 115: 77-80.
- 22) BOCCI V. Ozone as Janus. *Mediators Inflamm* 2004; 13: 3-11.
- 23) WOLFF HH. Die behandlung peripherer durchblutungsstörungen mit ozon. *Erfahr hk* 1974; 23: 181-184.
- 24) NOGALES CG, FERRARI PH, KANTOROVICH EO, LAGEMARQUES JL. Ozone therapy in medicine and dentistry. *J Contemp Dent Pract* 2008; 9: 75-84.
- 25) MORREY BF, DUNN JM, HEIMBACH RD, DAVIS J. Hyperbaric oxygen and chronic osteomyelitis. *Clin Orthop Relat Res* 1979; 144: 121-127.
- 26) AZARPAZHOOH A, LIMEBACK H. The application of ozone in dentistry: a systematic review of literature. *J Dent* 2008; 36: 104-116.
- 27) STEINHART H, SCHULZ S, MUTTERS R. Evaluation of ozonated oxygen in an experimental animal model of osteomyelitis as a further treatment option for skull-base osteomyelitis. *Eur Arch Otorhinolaryngol* 1999; 256: 153-157.